

# BONE BRIDGE IN SLOT TECHNIQUE FOR MENISCAL TRANSPLANTATION

BRIAN J. COLE, MD, MBA, JEFF A. FOX, MD, STEPHEN J. LEE, BA, and JACK FARR, MD

The menisci play a crucial role in knee function through optimizing contact mechanics (increasing contact area and distributing contact stresses), providing anteroposterior stability, articular cartilage nutrition and proprioception. It is well known that the post-meniscectomized knee can lead to degenerative changes that result in significant pain and disability. Meniscal transplantation attempts to restore the normal structure and function to the knee joint. Several studies suggest that anatomic bony fixation of the anterior and posterior horns are necessary to approximate normal knee contact mechanics. The purpose of this chapter is to describe the indications, preoperative planning, operative technique, postoperative rehabilitation, and results of the bone bridge in slot technique for meniscal allograft transplantation.

**KEY WORDS:** meniscal allograft, meniscal transplantation, bone bridge in slot, meniscectomy, meniscus  
© 2003 Elsevier Inc. All rights reserved.

It is well known that after a meniscectomy degenerative changes are more likely to evolve.<sup>1-4</sup> Today, surgeons place a premium on saving the meniscus whenever possible. Unfortunately, there remain a large number of patients who have undergone prior meniscectomy. Additionally, irreparable meniscus tears do occur leading to an at-risk population for the development of postmeniscectomy arthrosis. The poor function and disability associated with the symptomatic meniscectomized knee is the impetus behind meniscus transplantation. Meniscus replacement is performed in an effort to restore normal knee biomechanics and stave off the progression of degenerative change. The first meniscal transplant was performed in 1984.<sup>5</sup> Since then, several studies have demonstrated that meniscus transplantation increases contact area and decreases contact pressure and meniscectomy-related impairment.<sup>6-8</sup>

There are several techniques for allograft meniscus transplantation. A bone bridge technique (where the relationship between the anterior and posterior horns is maintained through a bony connection) has been used for several years.<sup>9</sup> We use a system developed in collaboration with two of the senior authors (JF and BJC) produced by Regeneration Technologies Incorporated (Alachua, FL). Potential advantages include: 1) maintaining the proper

relationship between the anterior and posterior horn attachment sites, 2) decreasing positional error 3) and firm anatomic attachments allowing the meniscus to "capture the femoral condyle" potentially restoring meniscus function and normalizing tibiofemoral contact pressures. The technique of preparing the donor meniscus bone bridge and recipient slot is presented in this article.

## INDICATIONS

The indications for transplantation continue to evolve as the benefits become better elucidated. Fundamental requirements include a stable knee, the absence of ipsilateral angular malalignment, and low grade arthrosis. The ideal candidate for allograft meniscus transplantation is the symptomatic patients with prior meniscectomy, persistent pain in the involved compartment with relatively intact articular cartilage (ie, less than grade III), normal alignment, and a stable joint. There is no upper chronological age limit, but it is the author's experience that patients older than 50 years have commonly developed a degree of arthritis that prevents them from being a candidate for the procedure.

Simultaneous or staged ligament reconstruction or realignment procedures are performed as indicated. Even a few degrees of angular malalignment with deviation toward the involved compartment compared with the contralateral limb is an indication for osteotomy. Significant articular disease (ie, late grade III or IV) and radiographic femoral condyle flattening or marked osteophyte formation are generally associated with inferior results and are considered the most common contraindications. Localized chondral defects should be treated concomitantly. Additional contraindications include inflammatory arthritis, obesity, and previous infection. Most importantly, despite data supporting the potential of meniscus allograft transplantation to prevent the onset or progression of postmeniscectomy arthrosis, it remains critical that patients are

---

From the Department of Orthopedic Surgery and Anatomy, Rush-Presbyterian-St. Luke's Medical Center, Chicago, IL; the Central States Cartilage Restoration Center, Central States Orthopedic Specialists, Tulsa, OK; the Northwestern University Feinberg School of Medicine, Chicago, IL; and the Cartilage Restoration Center of Indiana, Associate Clinical Professor of Orthopedic Surgery, Indiana University School of Medicine, Indianapolis, IN.

Address reprint requests to Brian J. Cole, MD, MBA, Director, Rush Cartilage Restoration Center, Associate Professor, Department of Orthopedic Surgery and Anatomy (Conjoint), Rush-Presbyterian-St. Luke's Medical Center, 1725 W. Harrison St., Suite 1063, Chicago, IL 60612.

© 2003 Elsevier Inc. All rights reserved.

1060-1872/03/1102-0009\$30.00/0

doi:10.1053/otsm.2003.35900

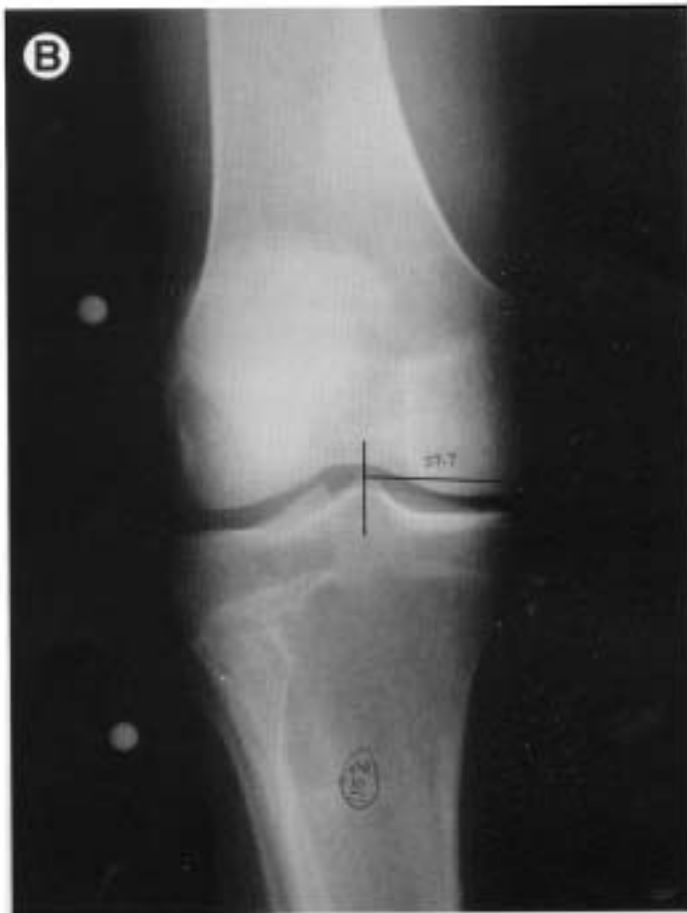
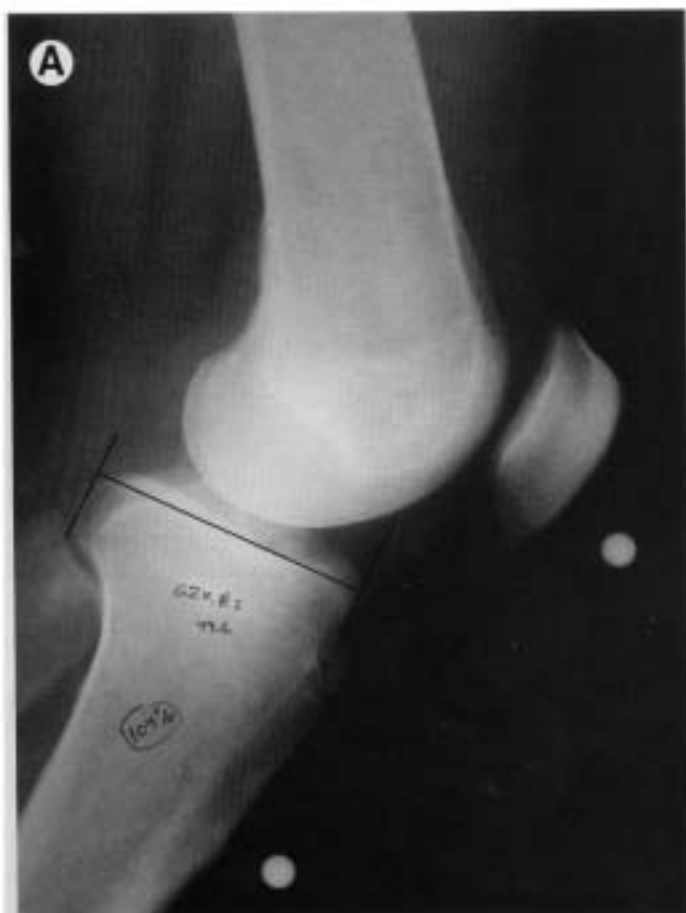
Fig 1. (A) Anteroposterior and (B) lateral radiograph with measurements corrected for magnification used to determine the appropriately sized meniscus allograft (see text for details).

sufficiently symptomatic to warrant and benefit from this complex intervention.

### GRAFT SELECTION

There are several graft choices available which include fresh, fresh frozen, and cryopreserved. Present research

demonstrates no clear advantage to transplanting a graft with viable fibro-chondrocytes. *Frozen grafts* result in non-viable fibro-chondrocytes, however the collagen framework is largely preserved in nonhuman studies.<sup>10</sup> *Cryopreserved* grafts are frozen in glycerol to preserve cell membrane and donor cell viability.<sup>11</sup> Either method is acceptable.

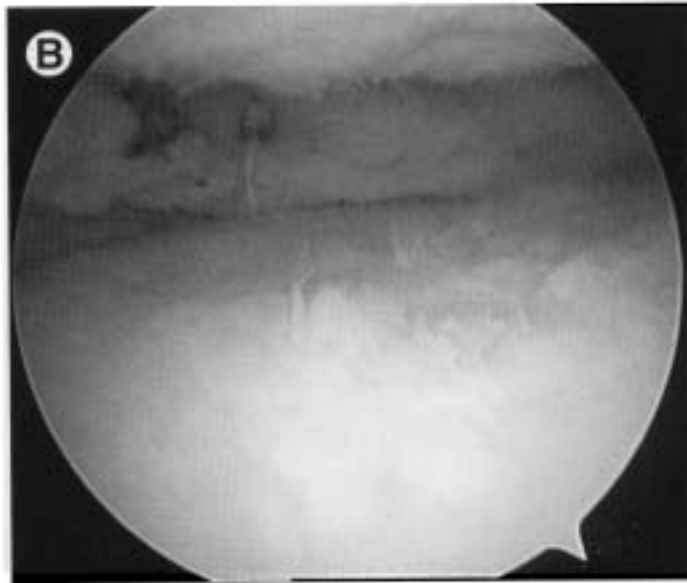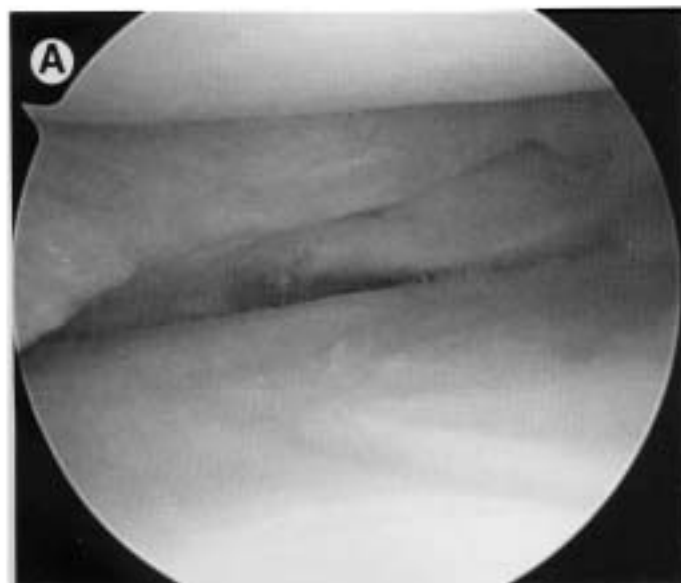
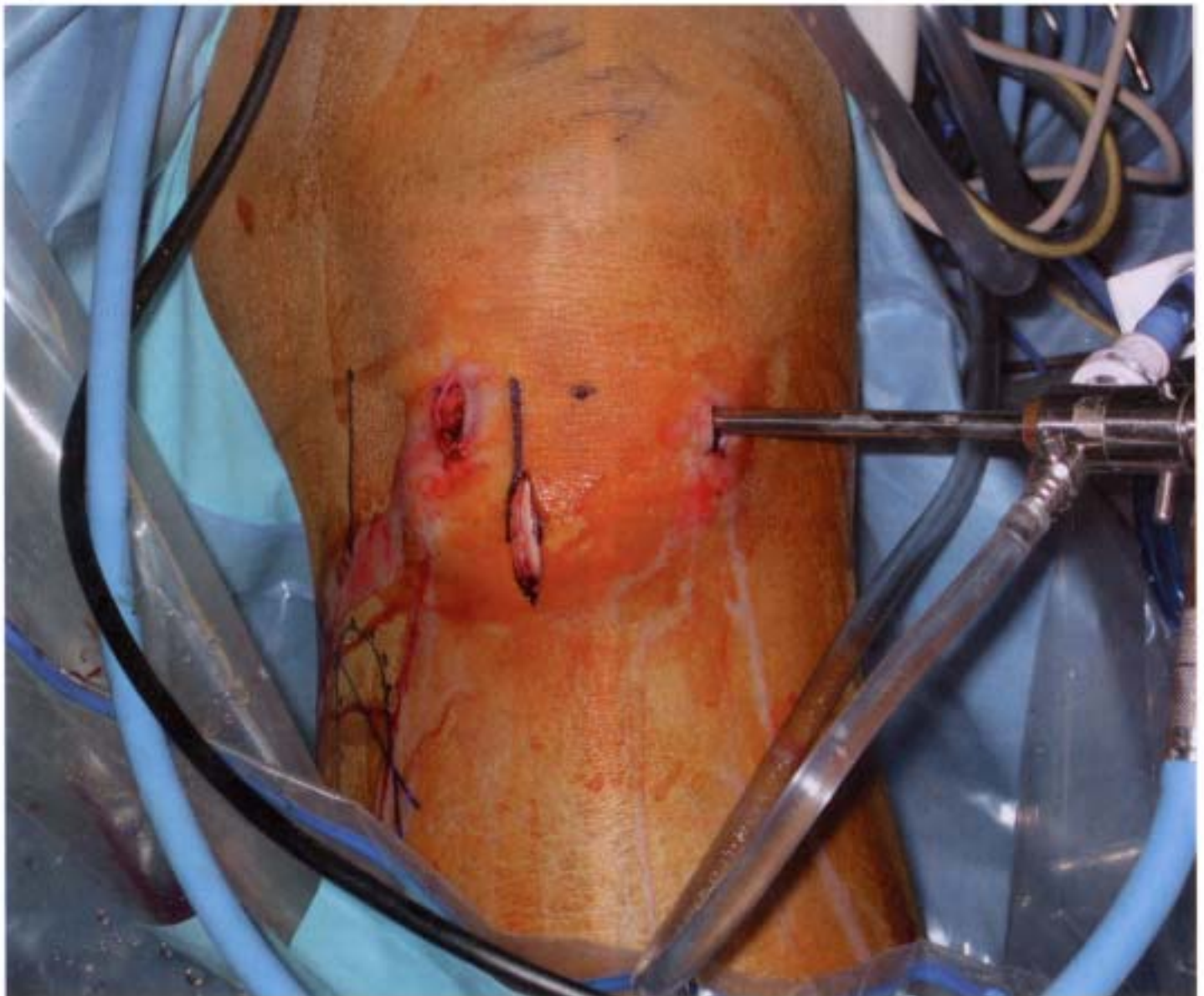
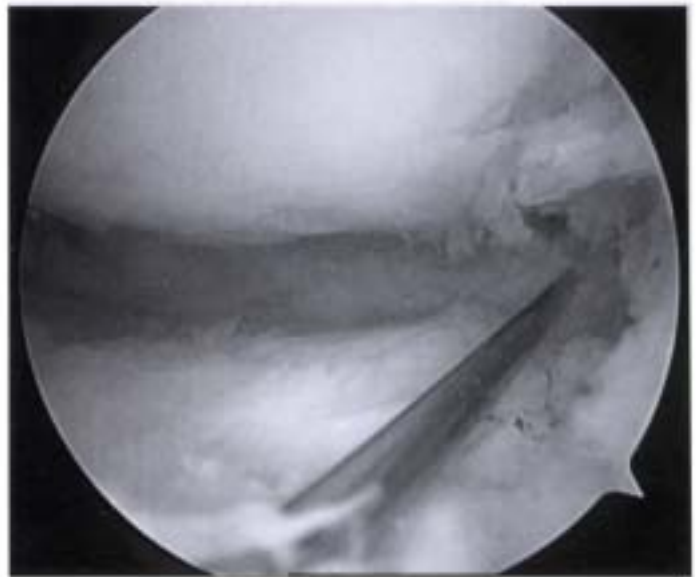


Fig 2. (A) Arthroscopic view of a right knee of a 34-year-old male who had his lateral meniscus removed 5 years previously before and (B) after meniscal preparation with debridement to the periphery of the meniscocapsular junction.

**Fig 3.** Arthroscopic view of an 18 gauge spinal needle placed percutaneously to determine the appropriate location of the trans-patellar tendon incision established in line with the anterior and posterior horn insertion sites.



**Fig 4.** Clinical photograph demonstrating the location of the trans-patellar tendon incision placed just central to the ipsilateral working portal within the lateral one-third of the patellar tendon extending from the inferior pole of the patella to the level of the joint line.

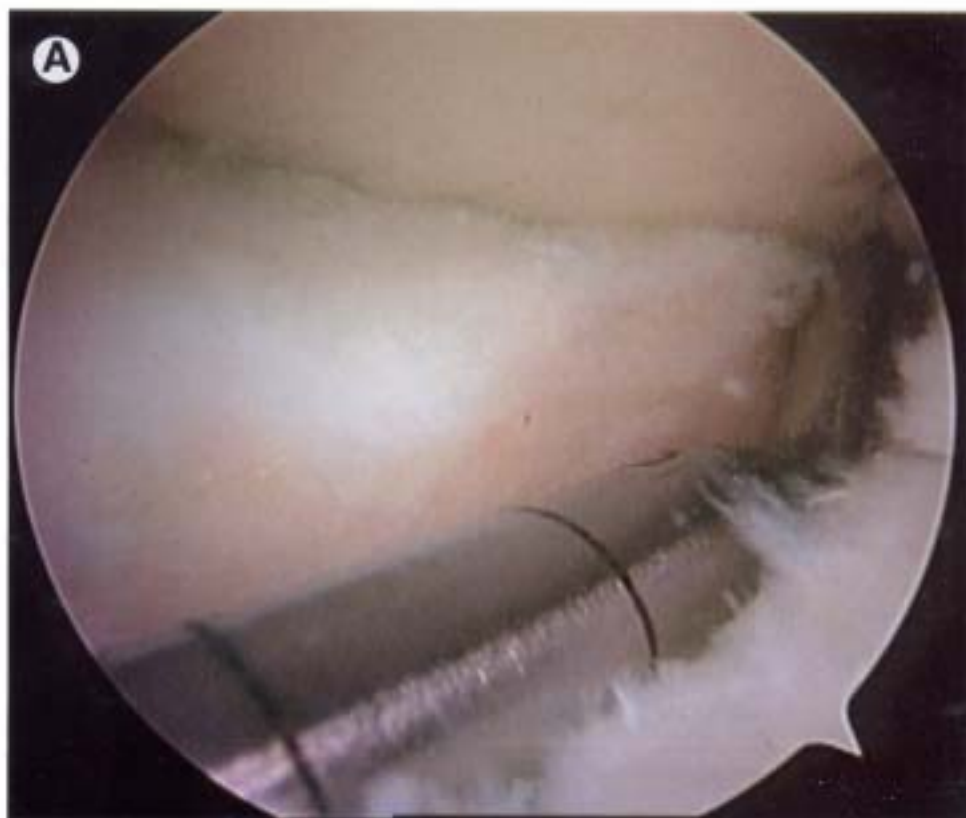
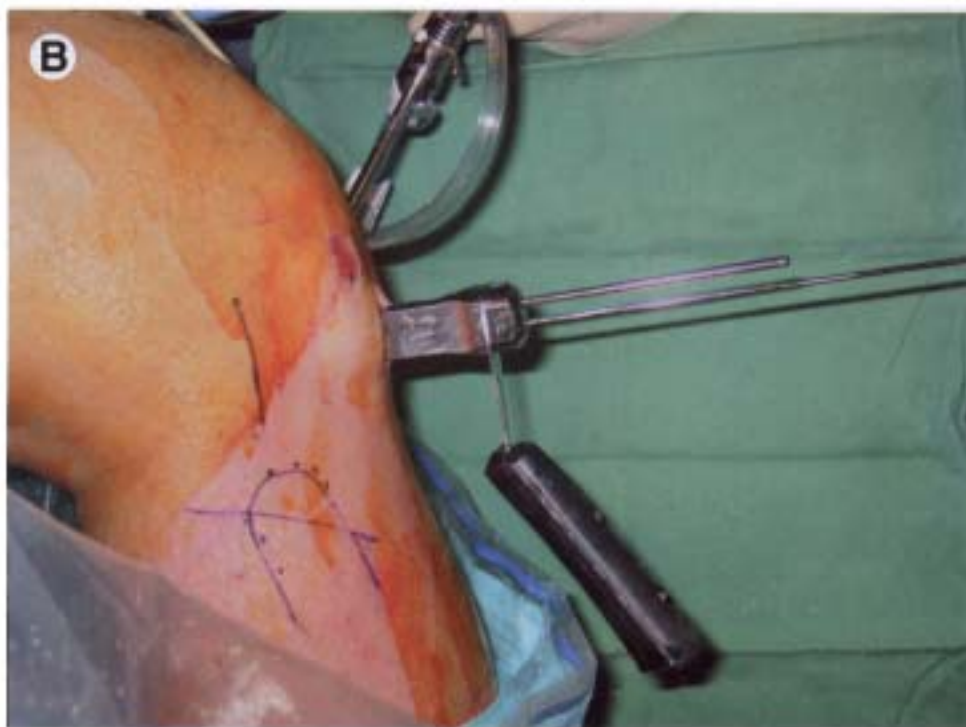

Fig 5. (A) Arthroscopic view of the depth gauge arm seated within the provisional slot created with an arthroscopic burr. (B) Clinical photograph of the drill guide in place with the guide position determined by a guide pin placed through the drill guide assembly.





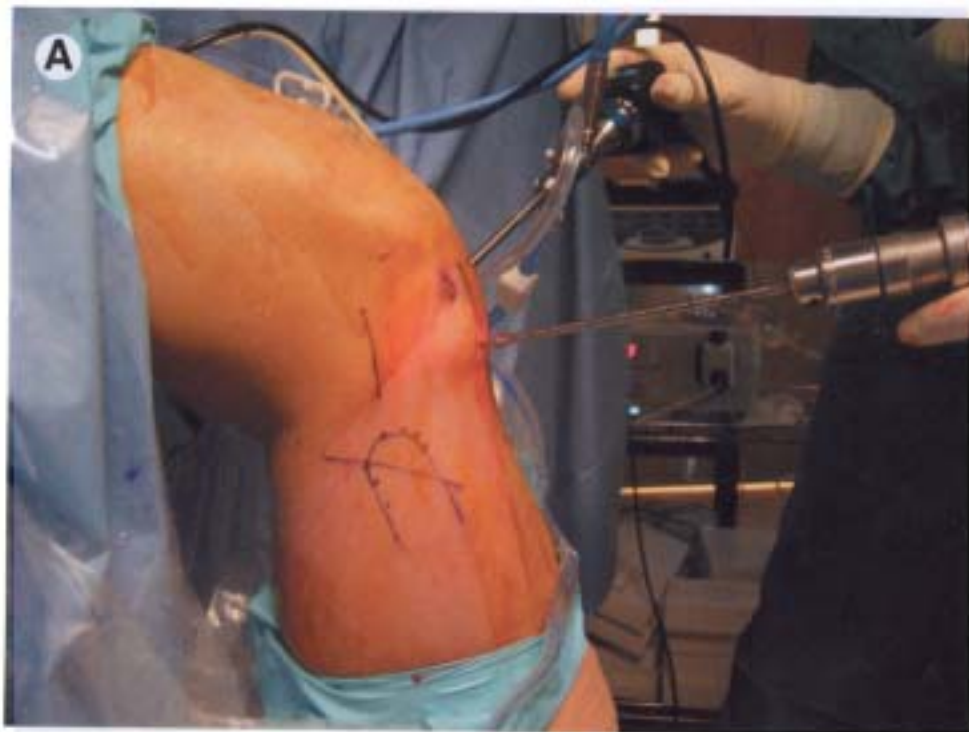

Fig 6. (A) Clinical photograph of the cannulated reamer placed over the guide wire used to predrill the slot. (B) Arthroscopically, the reamer head should be directly visualized.

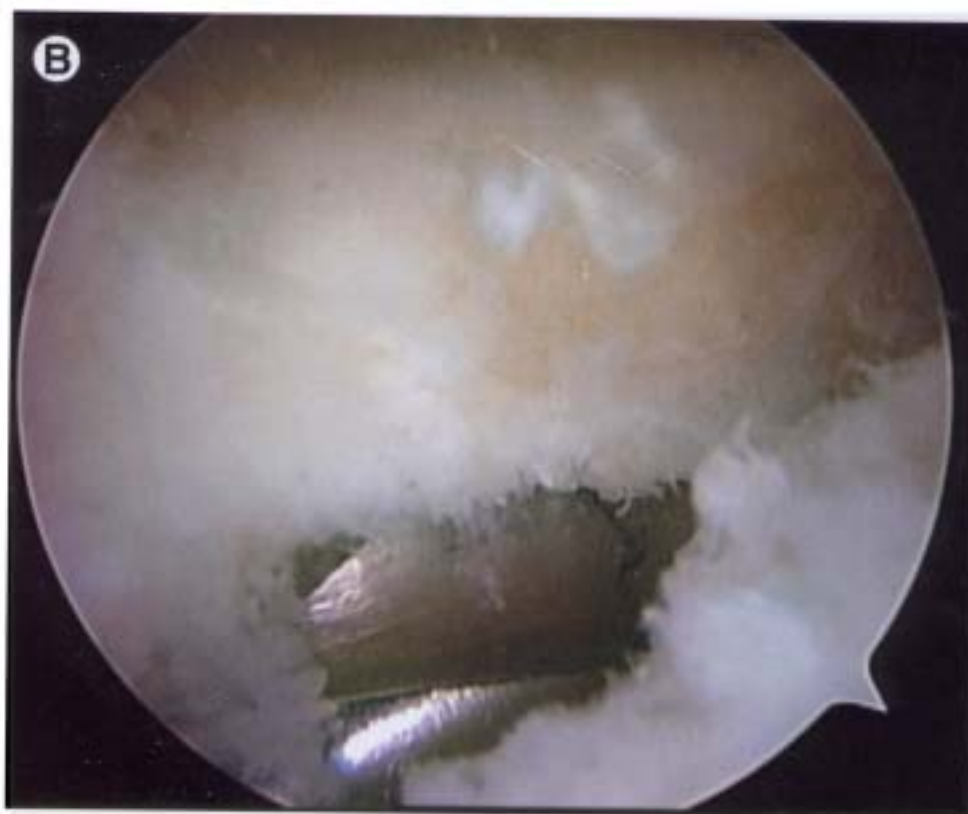

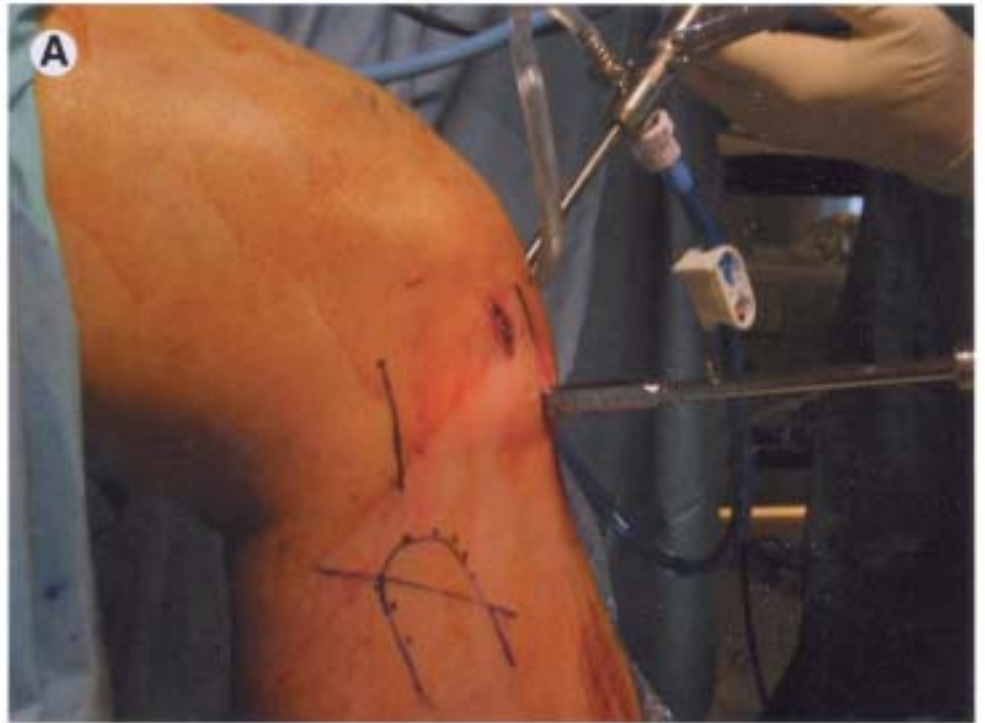
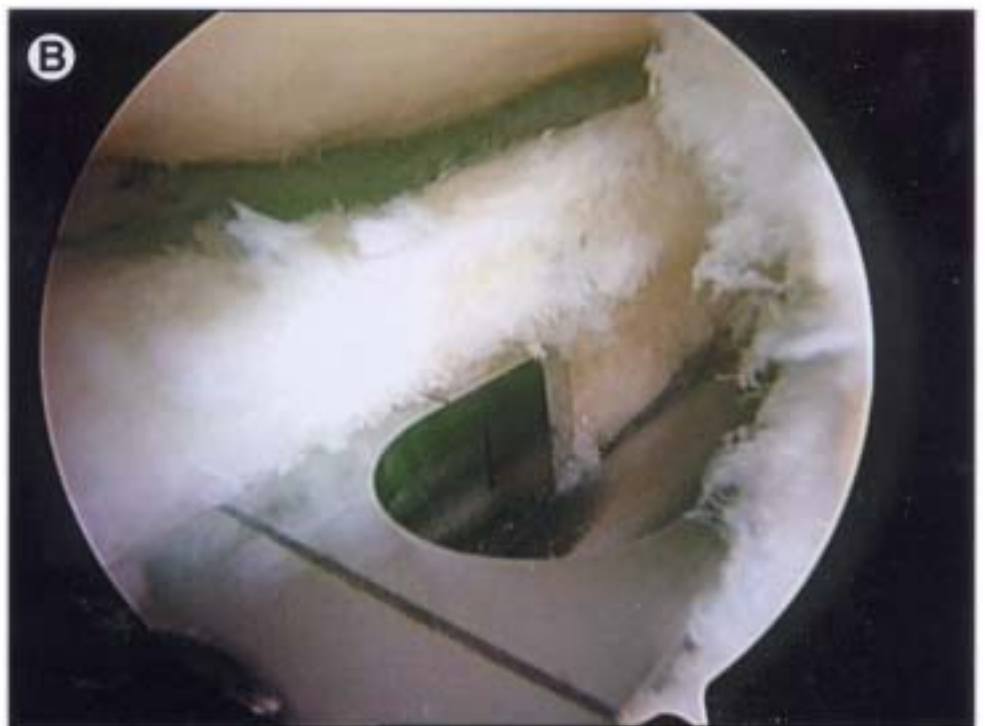

Fig 7. (A) Clinical photograph of the box cutting guide used to convert the cylindrical hole into the rectangular slot. (B) Arthroscopic visualization of the box cutting guide is important to avoid "snowplowing" beneath the articular surface as the guide is advanced.



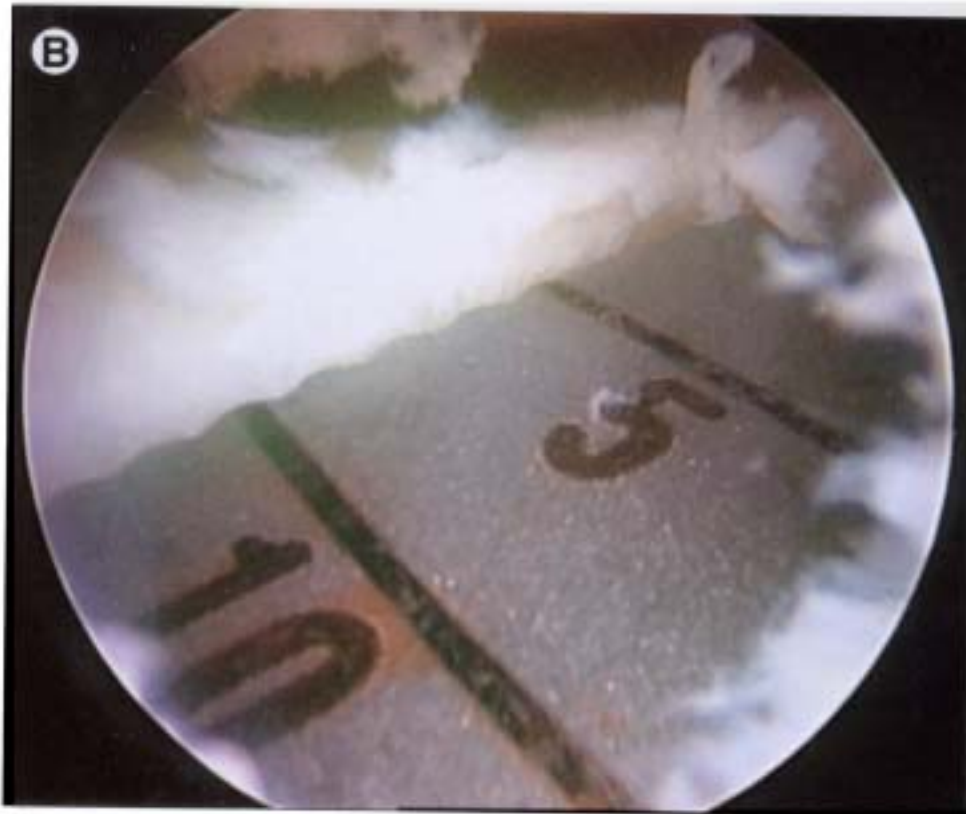
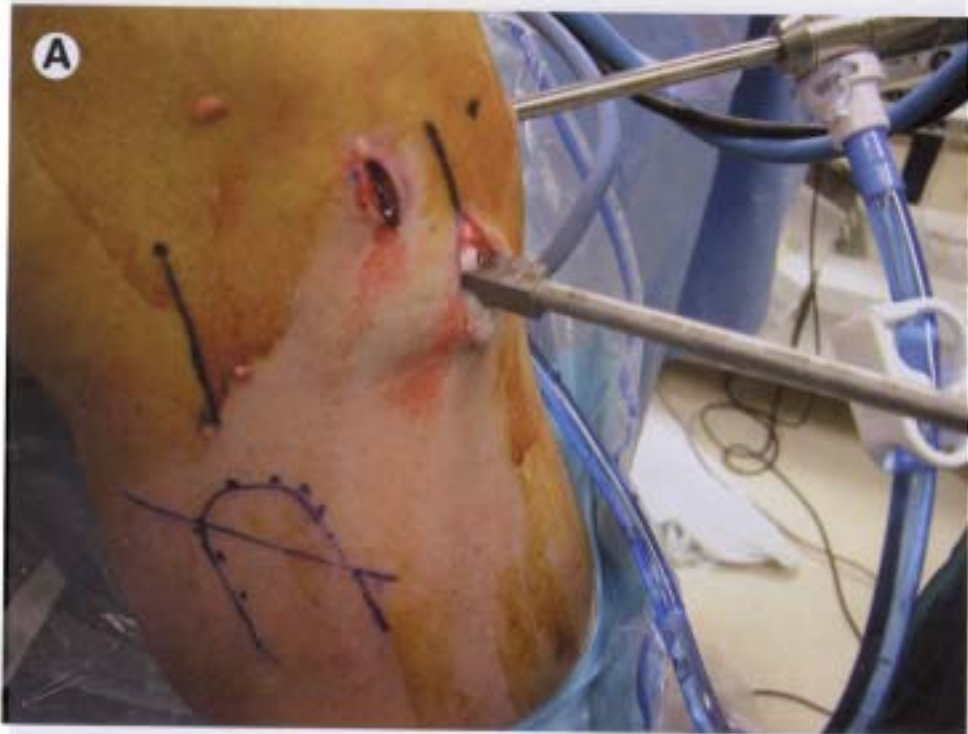
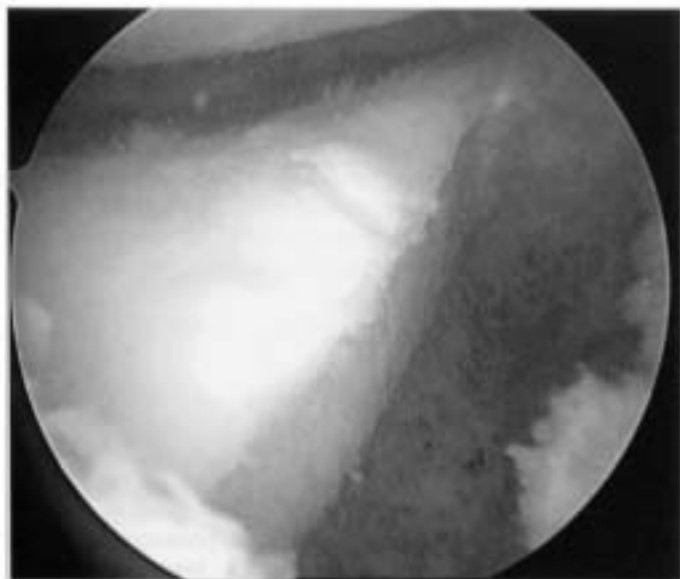


Fig 8. (A) Clinical and (B) arthroscopic view of the rectangular rasp used to finish the slot and enlarge it slightly to create a relatively loose fit for the meniscus as it is inserted into the rectangular slot.



**Fig 9.** Arthroscopic view of final slot prepared with all soft tissue and bone removed from entrance.

## PREOPERATIVE PLANNING

Diagnostic imaging includes a standard weight-bearing, anteroposterior (AP) radiograph of both knees in full extension, a nonweightbearing 45° flexion lateral view and an axial view of the patellofemoral joint. Additionally, a 45° flexion weight-bearing posteroanterior (PA) radiograph is recommended to help identify subtle joint space narrowing that traditional extension views may fail to identify. Preoperative magnetic resonance imaging (MRI) is not imperative, but may provide some information regarding the condition of the articular surface and biologic activity of the subchondral bone (ie, subchondral edema).

Allograft sizing is performed from plain AP and lateral radiographs following correction for magnification as de-

scribed by Pollard and co-workers<sup>12</sup> A standard AP and lateral radiograph is taken with a 10-cm template to adjust for magnification. The sagittal length of the medial meniscus is 80% and the lateral meniscus is 70% of the anterior-to-posterior tibial plateau dimension measured from lateral radiographs. The coronal width of the medial and lateral menisci nearly equals the distance from the respective tibial eminence to the periphery of the tibial compartment on AP films (Fig 1).

## SURGICAL TECHNIQUE


### ARTHROSCOPY

Arthroscopy is initiated with medial and lateral parapatellar portals. Diagnostic arthroscopy is performed to confirm the pathology and to remove the remnant meniscus to the vascular edge of the meniscus-capsular junction without compromising the synovial lining (Fig 2).

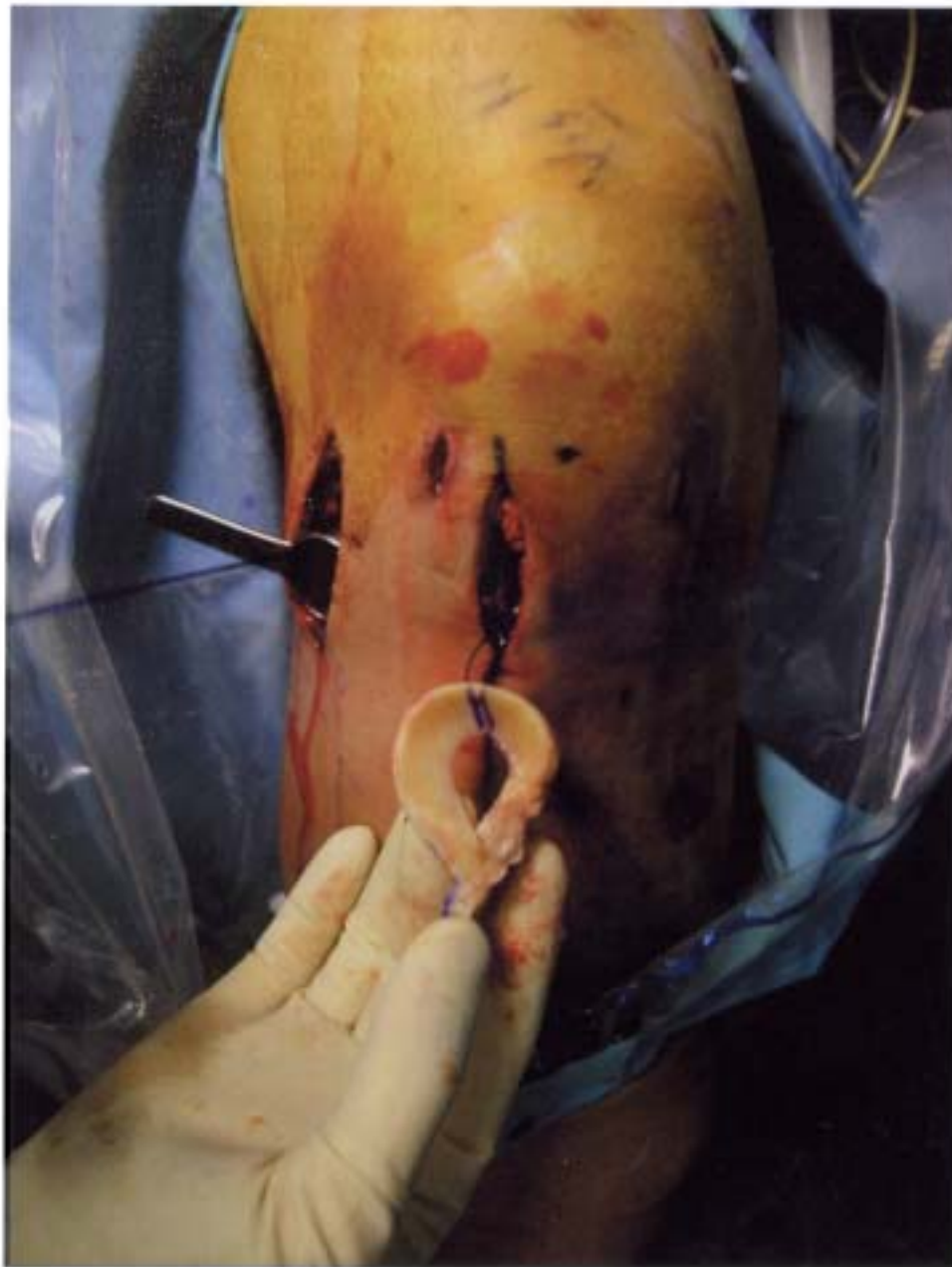A standard meniscus repair exposure positioned in line with the respective femoral epicondyle situated one-third above the joint line and two-thirds below the joint line is required to protect the neurovascular structures during inside-out meniscus repair. A Henning retractor (Linvatec, Largo, FL) is placed through this incision anterior to the gastrocnemius tendon to aid in directing the needles away from the popliteal structures and preventing injury to neurovascular structures.

Attention is returned to the intra-articular arthroscopy. An 18-gauge needle is used percutaneously to identify the location of the meniscal slot. It should line up with the anterior and posterior horns of the meniscus (Fig 3). A 3-cm incision is then made. This typically will be in line with the patellar tendon just central to the ipsilateral working portal incising within the medial (medial meniscus) or lateral (lateral meniscus) one third of the patellar tendon. While only the inferior half of this incision is used initially, it will be extended from the inferior pole to the

**Fig 10.** Meniscal sizing block is used to assure a uniform rectangular meniscal bone block.







**Fig 11.** Clinical photograph of the meniscus before insertion through the mini-arthrotomy placed in line with the lateral third of the patellar tendon. Note the traction sutures exiting the posterolateral incision with the neurovascular structures being protected by a Henning retractor.

level of the joint line at the time of meniscus insertion (Fig 4). A burr and radiofrequency device are used through this incision to develop a superficial path 2 to 3 mm deep, which allows the drill guide arm to be seated into this shallow tunnel. The guide pin is drilled through the inferior hole of the drill guide handle just to the posterior cortex of the tibia, but not through it (Fig 5). An 8-mm cannulated drill is placed over the guide pin and gently advanced to the posterior cortex of the tibia (Fig 6). To convert the subchondral circular hole into an intra-articular slot, the 8 mm box cutting guide is centered within the opening of the newly drilled tunnel created beneath the tibial surface and gently advanced while visualizing the vertical lines of the guide intra-articularly to avoid undermining or "snowplowing" beneath the tibial surface (Fig 7). The slot is cleaned of remaining debris using a pituitary rongeur or arthroscopic grasper and contoured using the 3-sided rectangular 7- and 8-mm hand rasp (Fig 8). The final slot is 8 mm in width and 10 mm in depth (Fig 9).

## ALLOGRAFT MENISCUS PREPARATION

The graft is thoroughly thawed in sterile saline. Soft tissue capsular remnants and excess tissue around the anterior and posterior horns is excised. An oscillating saw is used to create a 7-mm wide bone bridge that fully incorporates the bony insertion of the meniscal horns. A transverse cut made parallel to a line made 1 cm below the anterior and posterior horns is then made. Finally, any excess bone posterior to the posterior horn insertion is removed to allow full posterior seating of the graft within the slot. The prepared graft is sized using the rectangular sizing block. A No. 0 monofilament traction suture is placed at the junction of the body and posterior horns using a horizontal mattress technique (Fig 10).

## INSERTING THE MENISCUS

A nitinol pin (Arthrex, Inc., Naples, FL) is placed through a zone specific cannula and directed toward the postero-

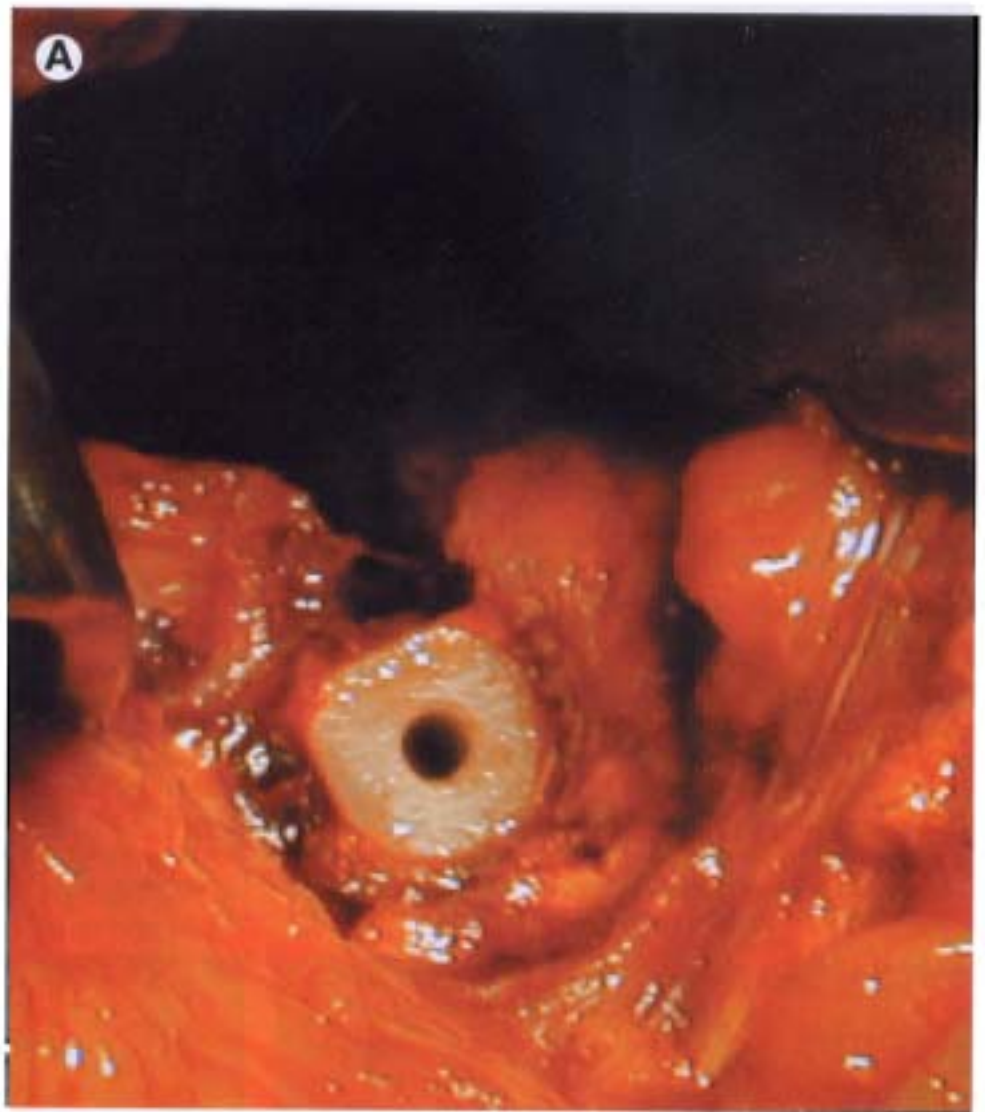
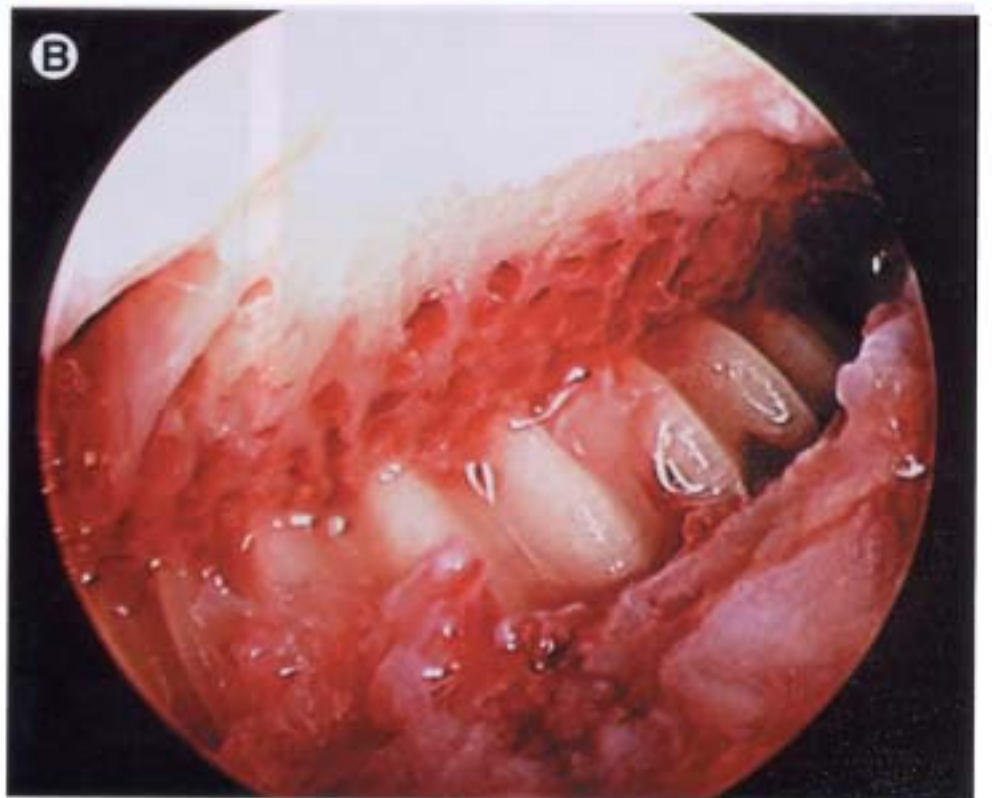


Fig 12. (A) Open and (B) arthroscopic view of the cortical bone interference screw approximated against the meniscus bone bridge within the recipient slot.



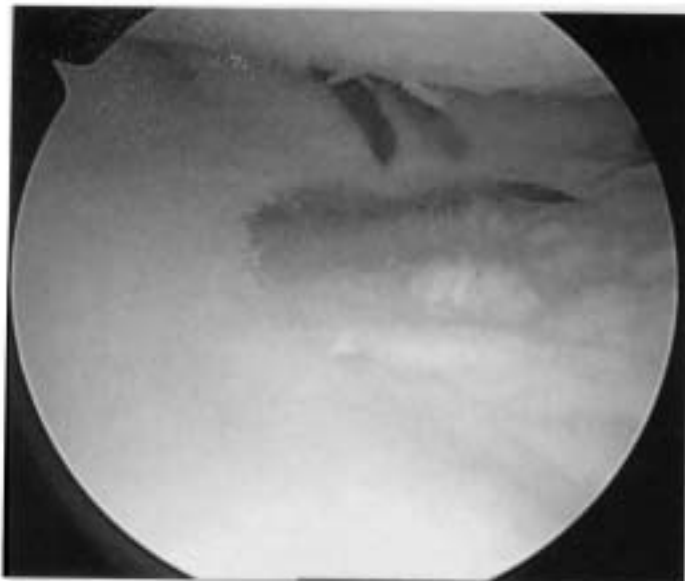


Fig 13. Arthroscopic view of the meniscus after inside-out meniscus repair.

lateral (lateral meniscus transplant) corner of the knee joint. The loop end is then retrieved from within the incision created earlier through the patellar tendon. The No. 0 monofilament suture ends are placed in the loop end of the nitinol pin and the pin is then pulled out the knee through the accessory posterolateral meniscal repair inci-

sion (Fig 11). During this step the knee may be flexed slightly and a varus load placed to open the lateral joint space. As the meniscus is pulled into the joint, the bone block is carefully seated in the prepared slot. The knee is cycled several times to seat the meniscus anatomically relative to the tibia and femur before fixation.

The block and slot are then tapped with a 7 tap placed central to bone block so as to compress the block and meniscus toward the ipsilateral compartment. Usually a 7 mm × 20 mm Cortical Interference bone screw (RTI, Alachua, FL) is placed (Fig 12). The meniscus is then sutured to the periphery of the knee. This is performed with 8 to 10 vertical mattress sutures using No. 2 to 0 Ethibond (Ethicon, Inc., Somerville, NJ) placed on the dorsal and ventral surface of the meniscus (Fig 13). The most anterior portion of the meniscus may need to be sutured with a combined open and arthroscopic technique.

## REHABILITATION

Postoperative treatment after allograft meniscus replacement is similar to autogenous meniscal repairs. We divide our protocol into three phases. Phase one involves the first 6 weeks. For the first two postoperative weeks, partial weight bearing is allowed in a hinged-knee immobilizer locked in full extension. Heel slides, quad sets, patellar mobilization, and straight leg raises are begun immediately with the brace unlocked. From 2 to 6 weeks, weight bearing is allowed as tolerated with crutches and at 4

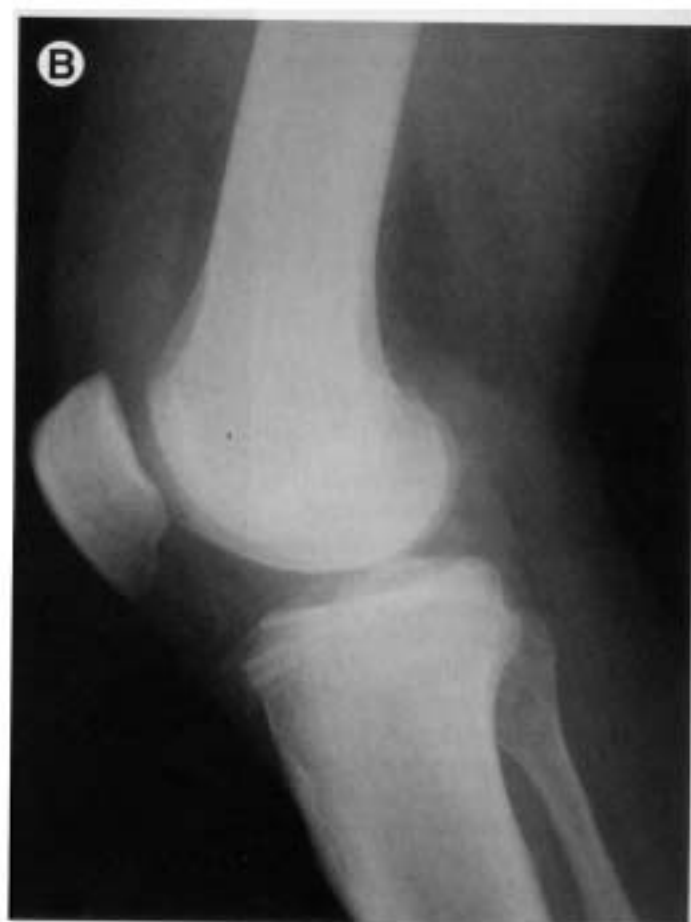
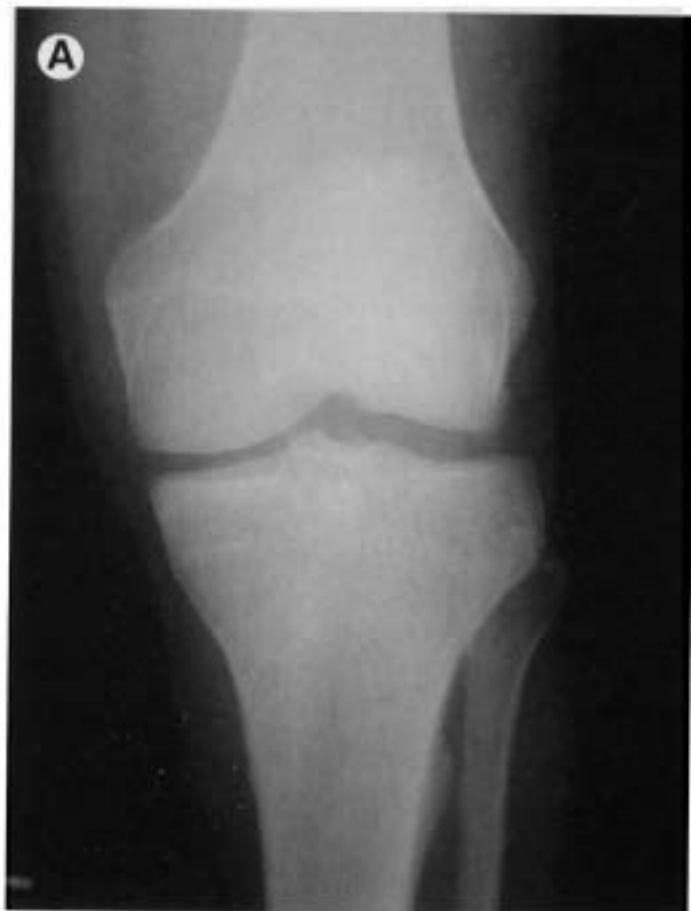
Fig 14. Postoperative radiographs at 6 months. (A) Anteroposterior and (B) lateral radiograph demonstrating excellent bone bridge incorporation within the slot and the cortical interference screw adjacent to the bridge.



weeks, crutches are discontinued if gait has normalized. The brace is discontinued at 6 weeks if the patient can ambulate without a limp. Exercises are advanced to allow closed chain exercises and terminal knee extensions. Weight bearing with flexion beyond 90° is minimized for the first six postoperative weeks.

Phase II (8 to 12 weeks postoperative) allows full weight bearing without crutches and full active range of motion. Progression of closed chain activities continues, hamstring work is initiated, lunges are allowed from 0 to 90° of flexion, and proprioception exercises and leg presses are permitted from 0 to 90°.

Phase III (12 to 16 weeks postoperative) exercises are progressed from phase II with the addition of functional activities such as single leg hops, a slow progression of in-line jogging to running, plyometrics, slideboard, and sport specific drills. Full activities are permitted at 4 to 6 months.

## RESULTS

The results of meniscal allograft transplantation have been published by a variety of authors with good and excellent results ranging from 50 to 100% with follow-up as long as 14 years.<sup>13-23</sup> Poor results are generally associated with the use of irradiated menisci, the absence of bony fixation of the meniscal insertion sites and in patients who have grade IV change in the involved compartment.

Between September 1997 and September 2002, the senior author (BJC) performed 86 transplants with 38 patients having a minimum follow-up of 24 months. Of the 38 patients, two failed within 12 months leaving 36 patients for evaluation. In this series, all medial meniscus transplants (23) were performed using the double bone plug technique, and all lateral (13) were performed using the keyhole technique (Arthrex, Inc., Naples, FL). Twenty patients underwent isolated meniscus transplantation and 16 patients had combined procedures. Overall, there were significant improvements in Modified Cincinnati, IKDC, Lysholm, and SF-12 physical component scores. Eighty-six percent were completely satisfied with the procedure and 94% said they would have the surgery again.

As this is a relatively new technique, there are no published results that specifically report on the bridge in slot configuration. Two of the authors (BJC and JF) recently reviewed the first 34 patients treated using the bridge in slot technique. At an average of 12 months (range, 6 to 24) after surgery, all bone bridges were healed radiographically and there was no evidence of bone bridge migration or displacement in either the anteroposterior or superoinferior direction (Fig 14). The allograft cortical bone interference screw maintained its original position within the tibial tunnel in all cases and demonstrated varying degrees of incorporation depending on the latest follow-up time point. There were no tibial radiolucencies or cystic lucencies noted on any of the follow-up radiographs.

## CONCLUSIONS

Symptom relief after allograft meniscus transplantation is predictable even at midterm follow-up providing that the

indications are adhered to (ie, contraindicating patients with grade IV change) and that all comorbidities are addressed (ie, ligament insufficiency, malalignment). Clinical results demonstrate their effectiveness in alleviating pain, swelling and in improving knee function. The procedure is technically challenging and warrants reproducible techniques. The bridge in slot technique is a relatively straight-forward approach that overcomes some of the limitations of other bone bridge procedures. The procedure can be performed for both medial and lateral meniscus allograft reconstruction and has the additional benefit of generally shorter operating room times and reliable anatomic fixation through the use of the cortical bone interference screw.

## REFERENCES

1. Fairbank TJ: Knee joint changes after meniscectomy. *J Bone Joint Surg Br* 30:664-670, 1948
2. Dandy DJ, Jackson DW: Meniscectomy and chondromalacia of the femoral condyle. *J Bone Joint Surg Am* 57:1116-1119, 1975
3. Johnson RJ, Kettelkamp DB, Clark W: Factors affecting late results after meniscectomy. *J Bone Joint Surg Am* 56:719-729, 1974
4. Tapper EM, Hoover NW: Late results after meniscectomy. *J Bone Joint Surg Am* 51:517-526, 1969
5. Milachowski KA, Weismeier K, Wirth CJ: Homologous meniscus transplantation. Experimental and clinical results. *Int Orthop* 13:1-11, 1989
6. Arnoczky SP, Milachowski KA: Meniscal allografts: Where do we stand? in Ewing JW (ed): *Articular Cartilage and Knee Joint Function: Basic Science and Arthroscopy*. New York, Raven, 1990, pp 129-136
7. Bylski-Austrow DJ, Meade T, Malumed J, et al: Irradiated meniscal allografts: Mechanical and histological studies in the goat. *Trans Orthop Res Soc* 17:175, 1992
8. Jackson DW, Whelan J, Simon TM: Cell survival after transplantation of fresh meniscal allografts. DNA probe analysis in a goat model. *Am J Sports Med* 21:540-550, 1993
9. Goble EM, Kane, SM, Wilcox, TR, et al: Meniscal allografts, in McGinty JB, Caspari RB, Jackson RW (eds): *Operative Arthroscopy*. Philadelphia, Lippincott-Raven, 1996, pp 317-331
10. Graham W, Smith D, McGuire M: The use of frozen stored tendons for grafting: An experimental study. *J Bone Joint Surg Am* 37:624, 1955
11. Kuhn JE, Wojtyls EM: Allograft meniscus transplantation. *Clin Sports Med* 15:537-536, 1996
12. Pollard ME, Kang Q, Berg EE: Radiographic sizing for meniscal transplantation. *Arthroscopy* 11:684-687, 1995
13. Garrett JC: Meniscal transplantation: A review of 43 cases with two to seven year follow-up. *Sports Med Arthrosc Rev* 1:164-167, 1993
14. van Arkel ER, de Boer HH: Human meniscal transplantation. Preliminary results at 2 to 5-year follow-up. *J Bone Joint Surg Br* 77:589-595, 1995
15. Cameron JC, Saha S: Meniscal allograft transplantation for unicompartmental arthritis of the knee. *Clin Orthop* 337:164-171, 1997
16. Noyes FR, Barber-Westin SD, Butler DL, et al: The role of allografts in repair and reconstruction of knee joint ligaments and menisci. *Instr Course Lect* 47:379-396, 1998
17. Cole BJ, Harner, CD: Degenerative arthritis of the knee in active patients. *J Am Acad Orthop Surg* 7:389-402, 1999
18. Stollsteimer GT, Shelton WR, Dukes A, et al: Meniscal allograft transplantation: A 1- to 5-year follow-up of 22 patients. *Arthroscopy* 16:343-347, 2000
19. Rodeo SA: Meniscal allografts—Where do we stand? *Am J Sports Med* 29:246-261, 2001
20. Rath E, Richmond JC, Yassir W, et al: Meniscal allograft transplantation. Two- to eight-year results. *Am J Sports Med* 29:410-414, 2001
21. Wirth CJ, Peters G, Milachowski KA, et al: Long-term results of meniscal allograft transplantation. *Am J Sports Med* 30:174-181, 2002
22. van Arkel ER, de Boer HH: Survival analysis of human meniscal transplantations. *J Bone Joint Surg Br* 84:227-231, 2002
23. Ryu RK, Dunbar VWH, Morse GG: Meniscal allograft replacement: A 1-year to 6-year experience. *Arthroscopy* 18:989-994, 2002